


## ARTIGO DE PESQUISA (CIENTÍFICO OU TÉCNICO)

# Surgical training in cadaveric model of intraluminal occlusion of the middle cerebral artery in rats, using limited resources

Fredy Leonardo Carreño Hernandez<sup>1\*</sup> , Juan Pablo Quintanilla<sup>2</sup>, Fernando P Cardenas<sup>2</sup><sup>1</sup> School of Medicine, Universidad de los Andes Bogotá, D.C., Colombia.<sup>2</sup> Neuroscience and Behavior Laboratory, School of Psychology, Universidad de los Andes Bogotá, D.C., Colombia

**How to cite:** Carreño Hernandez FL, Quintanilla JP, Cardenas FP. Surgical training in cadaveric model of intraluminal occlusion of the middle cerebral artery in rats, using limited resources. *Bio M Res Tech.* 2024;4(1):e00072023. <https://doi.org/10.4322/2675-9225.00072023>

## Abstract

Ischemic stroke is the second leading cause of death and the leading cause of disability in the world. This is because current interventions are effective only in a narrow window of time. To prolong the period in which the interventions are effective, several in vivo animal models have been developed, among which an ischemic stroke is induced by introduction of an intraluminal catheter through the internal carotid artery or by inoculation of a thrombus into the common carotid artery. However, these models are not easy to execute in regions where access to specialized surgical material is difficult. We propose a study in a cadaveric model with Wistar rats with the aim of producing a surgical approach, like that achieved by introducing an intraluminal catheter at the base of the middle cerebral artery, using resources that are easily accessible to any laboratory. 40 rat carcasses, watchmaker tweezers, 0.17 mm diameter nylon suture and silicone were used to produce catheters, office clips, disposable cauterizer, 0.6 mm diameter soft wire as vascular clamp and hypodermic needles G -22 and G-32. Two surgical techniques for intraluminal introduction and occlusion are described. It was possible to introduce the catheter to the middle cerebral artery between 33 and 45 minutes, with a value in Colombian pesos for the total supplies of 200,000 COP / 27 USD for reusable materials. Although the procedure was reproducible in all the animals used, it is necessary to run this model in-vivo to observe its reproducibility by testing different treatments.

**Keywords:** Brain Stroke, animal model, arterial obstruction, animal surgery, training.

## INTRODUCTION

Stroke consists of a reduction in cerebral blood flow that can be due to multiple causes, such as stroke. From those, ischemic are usually between 70% and 80% of all cases, and hemorrhagic accounts for 15%<sup>1</sup>. Ischemia is defined as a reduction in blood flow that alters normal cell function because of the brain being highly sensitive to it due to its high metabolic rate<sup>2</sup>. In addition, the brain depends on the supply of energetic substrates by the circulatory route as consequence of the absence of sources or deposits of these in this tissue<sup>3</sup>. Therefore, even brief periods of ischemia can cause damage and death of the affected brain tissue, as they result in deprivation of glucose and oxygen, producing ATP depletion, changes in the concentrations of sodium, potassium and calcium, lactic acid, accumulation of free radicals, cellular edema, and activation of proteolytic processes<sup>4</sup>. This culminates in cell death and brain tissue injury, on account of a combination of oxidative stress, excitotoxicity, inflammation, and apoptosis<sup>5</sup>.

\*Corresponding author: fredyleonardoc@gmail.com

**Competing interests:** No conflicts of interest declared concerning the publication of this article.

Received: May 10, 2023. Accepted: January 11, 2024.



This is an Open Access article distributed under the terms of the Creative Commons Attribution License, which permits unrestricted use, distribution, and reproduction in any medium, provided the original work is properly cited.

Given the vulnerability of the brain to ischemia, current treatments consist of early restoration of blood flow to the affected region. The first line of intervention is recombinant tissue plasminogen activator (rtPA), which is the first and only agent approved for the treatment of ischemic stroke<sup>6</sup>. Although the tissue is reperfused, the cells of the penumbra (the region surrounding the nucleus of the ischemic zone) tend to die after the ischemia. To address this problem, other approaches have been investigated such as avoiding excitotoxicity or by activating protective processes of glial cells<sup>7</sup>. In addition, new strategies such as hyperbaric chambers, cold ischemia and barbiturate coma have been proposed to reduce reperfusion necrosis<sup>8,9</sup>. But barbiturate coma was ruled out two decades ago by Schwab et al.<sup>10</sup> when demonstrating inefficacy.

In this way, the existing animal models aim to produce a focal lesion from blood flow obstruction with consequent blood flow return to study therapeutic strategies<sup>11</sup>. Examples are animal models have shown that effective therapies work best between 15 and 30 minutes after the onset of ischemia and are rarely effective after 3 hours<sup>12</sup>. In rats, there are different models with the aim of producing a local infarction of anticipated size<sup>13</sup>, one of the most used for this purpose being the obstruction of the middle cerebral artery by inserting a catheter through the internal carotid artery<sup>14</sup>. However, this model has limitations in its execution in certain research centers due to the inaccessibility of surgical material and the cost of the required implements. Therefore, the objective of this study is to standardize in a cadaveric model, three surgical techniques to bring a catheter to the base of the middle cerebral artery to produce its reversible obstruction,

## MATERIALS AND METHODS

This work was based on standardized surgical models<sup>15,16</sup>, which highly specialized surgical material were modified or changed. Additionally, there is a video in supplay material to facilitate the surgical reproducibility.

### Animals

Forty Wistar rats with a range between 259 g min and 620 g max were used, with 64% female. Of these, 16 were used for one surgical technique, 17 for a second second surgical technique and 7 for a third surgical technique. All animals were sacrificed with institutional protocol which are based on established protocols<sup>17</sup>, and none of the animals used presented neck pathologies that could complicate the procedure. Animals were placed in a chamber to exchange air with 100% CO<sub>2</sub> between 5 to 10 minutes. Animal death was confirmed by complete cessation of breathing and mucocutaneous pallor. Animals used were donated by the Neuroscience and Behavior Laboratory of the Psychology Department of the Universidad de los Andes and by the Comparative Biology Unit of the Pontificia Universidad Javeriana. Since this procedure was performed on cadaveric models to standardize and refine a surgical procedure, no approval for ethics committee was needed.

### *Surgical Instruments and Price Record*

Materials and prices are listed in Table 1 for a surgical procedure.

### *Material preparation*

The tip of the ESD-14 tweezers and one of the ESD-15 tweezers were modified to obtain a rougher texture using a common emery wheel (See Figure 1). The rest of the tweezers were not modified. Common clips were molded into tissue spacers. Using two Needle carrier, the greater curvature was bent until an S-shape was obtained (See Figure 2). 3 types of catheters were produced using a G-22 needle and silicone. The catheter filaments were made of Nylon with a diameter of 0.17 mm, 3-0 propylene suture and 0.2 mm silk. To make the catheters, the bevel of the needle was removed, and the filament was inserted. The tip was immersed in hot silicone and the nylon was further inserted. The filament remained in the hot silicone for less than a second to avoid deforming it. It was observed under the stereoscope with 4X magnification to find deformities. In case irregularities were observed, the silicone tip was molded with P-1600 sandpaper and heated with the bulb of the stereoscope (See Figure 3).

**Table 1.** materials and instruments used

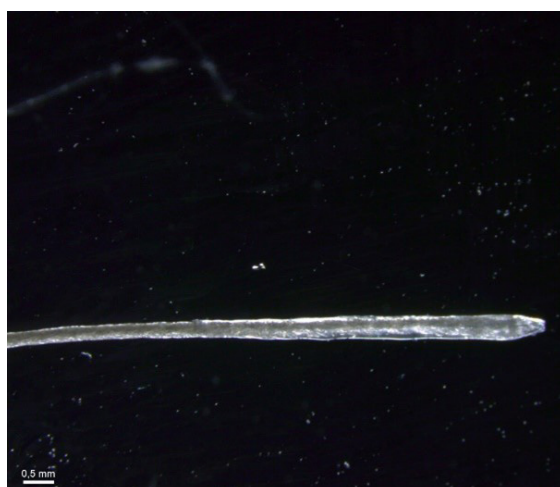Materials	Unit Price COP / USD
ESD-15 Curved Watchmaker's Tweezers x 3	10,000 / 2.72
EDS-14 watchmaker clamp straight x 1	9,000 / 2.45
*Box of common office clips x 1	1,000 / 0.27
*G-31 needle x 1	600 / 0.16
*Bovie AA01® cauterizer x 1	75,000 / 20.41
*Nylon 66 B-46 x 1	4,000 / 1.09
*Propylene sutures 0-6	10,000 / 2.09
*DMC cotton thread Lv 40 x 1	4,000 / 1.09
Claw pliers x 1	10,000 / 2.64
Needle holder x 3	22,000/ 4.08
*Nylon filament (diameter 0.17 mm) x 1	6,000 / 1.63
*G-22 hypodermic needle x 1	200 / 0.05
*G-25 needle	200 / 0.05
*Hot silicone (ethylene-vinyl acetate) x 1	200 / 0.05
Stereoscope x 1	1,700,000 / 462.52
electron microscope	70,000 / 18.48
*Sandpaper P-1600	1,000 / 0.27
Watchmaker glasses x 1	45,000 / 12.24
iris scissors	120,000 / 32.65
*Sweet wire (diameter 0.6mm) x 1	9,000 / 2.45
Scalpel Handle #3 x 1	10,000 / 2.72
with scalpel blade #15 x 1	200 / 0.05
<b>Total</b>	<b>2,055,000 / 599.11</b>
*Subtotal disposable materials	101,000 / 27.48
Subtotal reusable materials	1,954,000 / 531, 63

\*Disposable materials.

**Figure 1.** ESD-15 Curved Watchmaker's Tweezers and EDS-14 watchmaker clamp straight.



**Figure 2.** Common office clips such as tissue spacers.



**Figure 3.** Stereoscopic image of the tip of a catheter, proportion 0.5 millimeters.


The Cauterizer tip was bent with a needle holder (See Figure 4) and the G-31 needle was bent with the bevel down. A spring-shaped vascular clamp was made using the 0.06 mm diameter soft wire. The wire was molded using a rigid rod of 0.04 mm in diameter until obtaining the shape of a spring (See Figure 5). The Cauterizer tip was bent with a needle holder (See Figure 4) and the G-31 needle was bent with the bevel down. A spring-shaped vascular clamp was made using the 0.06 mm diameter softwire. The wire was molded using a rigid rod of 0.04 mm in diameter until obtaining the shape of a spring (See Figure 5). The Cauterizer tip was bent with a needle holder (See Figure 4) and the G-31 needle was bent with the bevel down. A spring-shaped vascular clamp was made using the 0.06 mm diameter soft wire. The wire was molded using a rigid rod of 0.04 mm in diameter until obtaining the shape of a spring (See Figure 5).

### ***Surgical technique***

Once the animal was sacrificed with CO<sub>2</sub>, it was placed in a supine position with its head away from the surgeon. Limbs were immobilized with adhesive tape. The neck was shaved using a minor razor blade



**Figure 4.** Hook-shaped cautery tip.



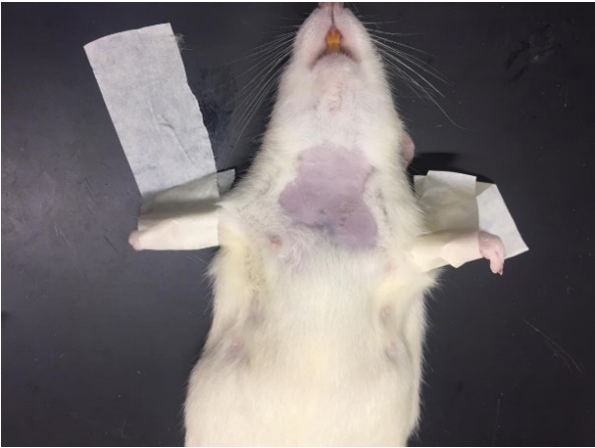**Figure 5.** Spring-shaped vascular clamp and its size in centimeters.

(See Figure 6). Once the neck was exposed, it was pulled with claw forceps and a 1.5 to 2 cm longitudinal cephalic-caudal incision was made, leaving the digital microscope on top of the animal for a better visualization of the tissues (See Figure 7). Blunt dissection with iris scissors was continued until the salivary glands were exposed. The tissue adjacent to the glands continued to be dissected with ESD-15 forceps without a modified tip, until the sternothyroid and sternocleidomastoid muscles were exposed.

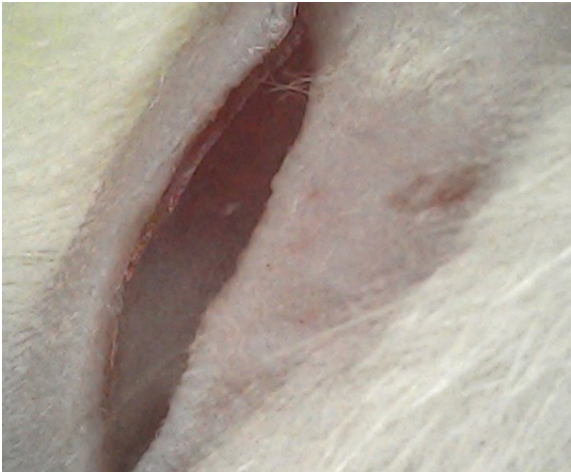Dissection continued between both muscles on the left side until the digastric muscle was observed. The fasciae between the three muscles were dissected until the carotid arteries were observed. The same tissue spacers previously used were re-positioned parallel to the sternohyoid and sternocleidomastoid muscles (See Figure 8). Having an adequate visual field, it must be possible to differentiate the internal from the external carotid artery, since the former is accompanied by the vagus nerve. The vascular bundle of the vagus nerve and the adjacent fasciae are dissected using unmodified ESD-15 forceps. The vascular clamp was placed on the common carotid to expose them (See Figure 9). Using the modified ESD15 forceps, the pterygopalatine and thyroid arteries were grasped to expose and cauterize them.

- **First Surgical Technique: Puncture and then introduction.**

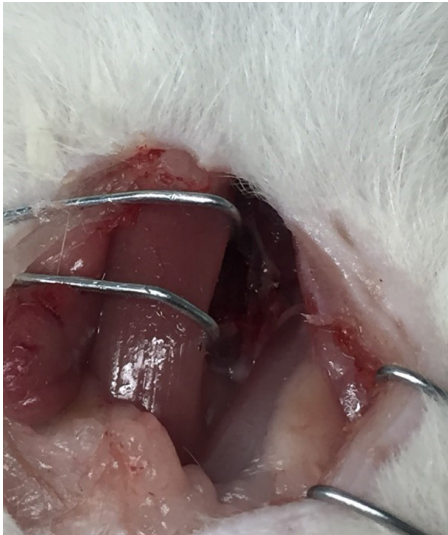Confirming that the external carotid artery can be moved more easily, the ESD-14 clamps were placed under the external carotid artery so that it is taut (See Figure 10). We make sure that



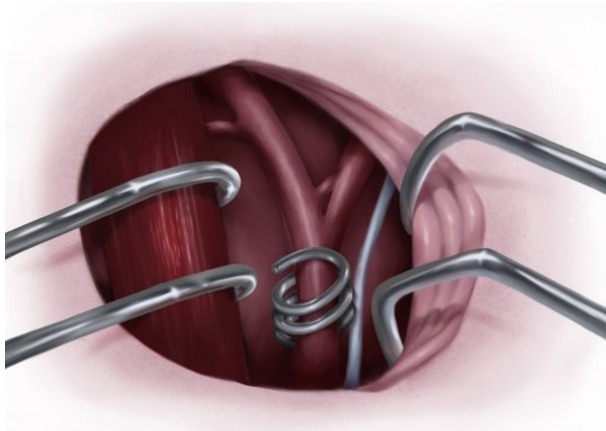
**Figure 6.** Disposition of the animal.



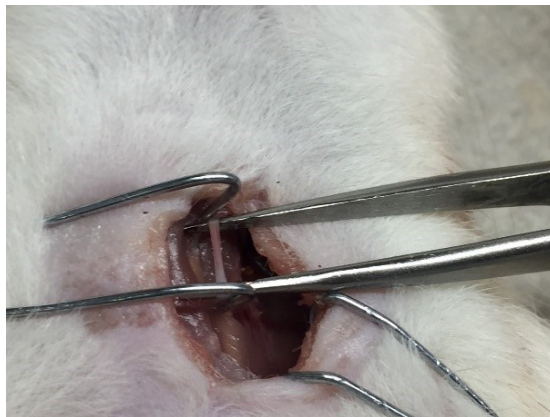
**Figure 7.** Longitudinal neck incision.



**Figure 8.** Sternocleidomastoid and sternohyoid muscles pulled.



**Figure 9.** Spring-shaped vascular clamp on the common carotid artery.




**Figure 10.** External carotid artery tensioned with EDS-14 watchmaker clamp straight.

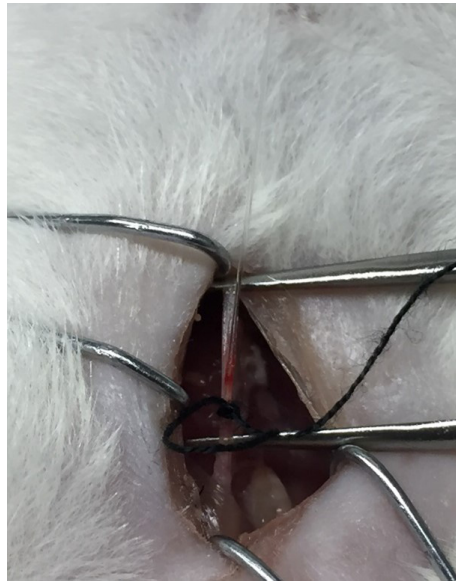
the ESD-14s are at the same height as the artery. With the G-31 hypodermic needle, the external carotid artery was punctured in its distal portion (See Figure 11). The incision made was slightly pushed and the catheter was introduced with the end that has silicone and it is taken to its most proximal portion to the carotid bifurcation (See Figure 12). Knots with 0-6 silk sutures were placed in the external carotid artery, in its cephalic portions, without obstructing flow. The catheter was brought up to the bifurcation and both carotid arteries were pulled so that they were parallel, and the catheter could continue through the internal carotid artery. External carotid flow was obstructed by closing the previously placed knot, and the distal end of the external carotid artery was cauterized. The external carotid artery was pushed in parallel and in the opposite direction to the internal carotid artery. The catheter was further introduced until resistance was felt and the vascular field was withdrawn.

- **Second Surgical Technique: Puncture and introduction at the same time.**

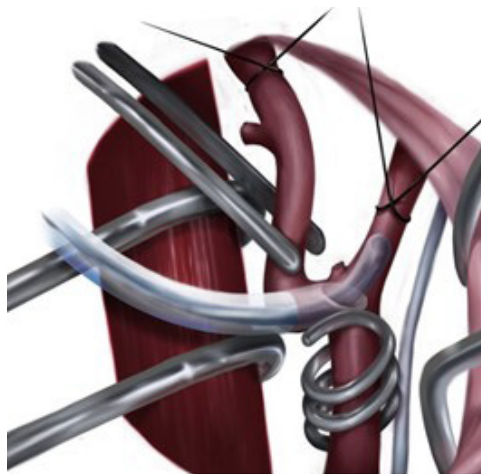
Confirming the free mobility of the external carotid artery, we proceed to obstruct the flow of the external carotid and internal carotid, in cephalic portions, using 6-0 propylene sutures. The catheter is inserted into a G-22 or smaller gauge Hypodermic needle and, holding the external carotid artery, a puncture is made at the caudal end of the external carotid artery (See Figure 13). With great care, the hypodermic needle is withdrawn, leaving the catheter inside, and it is taken to the internal carotid artery. The catheter continues to be introduced until resistance is felt, and with this the external carotid artery is finally completely obstructed and the vascular clamp is removed.



**Figure 11.** External carotid artery tensioned with EDS-14 watchmaker clamp straight.



**Figure 12.** First Surgical Technique. Puncture and then introduction.

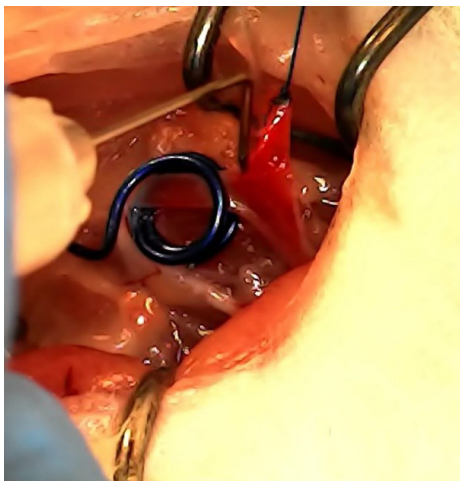


**Figure 13.** Second Surgical Technique. Puncture and introduction at the same time.



- **Third Surgical Technique: External carotid artery traction and puncture (traditional)**

Having isolated the external carotid artery, the cephalic flow is obstructed with two 6-0 propylene sutures. A cut of the artery is made in its distal portion between the sutures, the cauterizer must be used since the suture is hot-melt. The external carotid artery is placed parallel and opposite to the internal carotid artery. Using needle holders, the external carotid artery is pulled from the propylene suture. With a G-31 needle, an incision is made, and the catheter is inserted (see figure 14). The catheter is advanced to the internal carotid



**Figure 14.** Third Surgical Technique. External carotid artery traction and puncture (traditional).

- **Middle cerebral artery catheter evaluation**

A dissection of the brain was performed using watchmaker's forceps in search of the middle cerebral artery and whether the catheter was properly placed. Similarly, possible injuries caused by the catheter were examined.

## RESULTS

### Surgical techniques

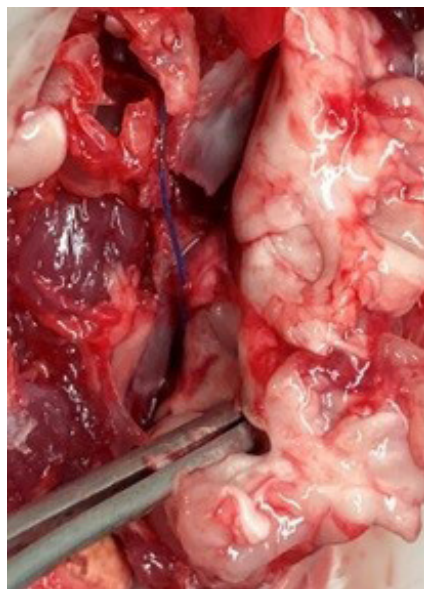The catheter managed to position itself in the internal carotid artery, with limitations in the first two techniques when introducing the catheter to the internal carotid artery and with greater ease for the third technique. The first surgical technique had the advantage of stability in the puncture of the needle and in the introduction of the catheter. But with the problem that, when introducing the catheter to the bifurcation of the carotid arteries, it requires using force. The second surgical technique presents opposite advantages and disadvantages, being that it does not present puncture stability, but does not require force in the carotid bifurcation. The third surgical technique offers the greatest ease of catheter introduction and delivery to the internal carotid artery. The tissue spacers did not generate any apparent injury and did not produce alterations in the morphology of the pulled muscles. One difficulty that was found is that if the needle is inserted to perform the arteriotomy, if it is inserted too far it can perforate the artery and limit the use of this technique. The average time was 15 minutes for the traction of the muscles and visualization of the vascular bundle, 27 minutes for the total dissection of the vascular bundle and 45 minutes for the introduction of the catheter to the internal carotid artery. There were no differences in time for the three surgical techniques.

- **Catheters Filament**

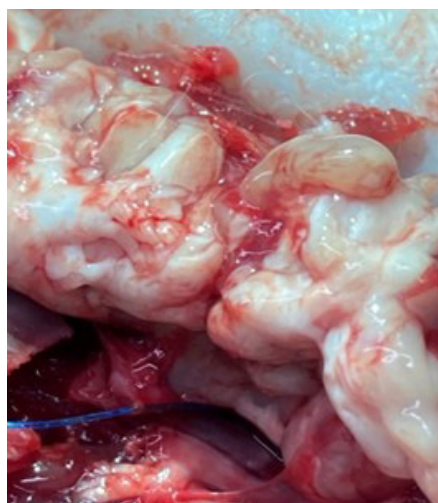
The silk filament, although it was the easiest to introduce, given its lack of rigidity, it did not reach the internal carotid artery. The propylene and nylon sutures did not present differences at the time of being used.

- **Middle cerebral artery obstruction**

Figures 15 and 16 show the catheter over the middle cerebral artery, with signs of subarachnoid hemorrhage. The result was similar in the three surgical techniques.



**Figure 15.** Propylene catheter on the middle cerebral artery.



**Figure 16.** Propylene catheter on the middle cerebral artery.

## DISCUSSION

Ischemic cerebrovascular disease is the second cause of mortality in the world and the first cause of disability in the world Similarly<sup>18</sup>, it presents many sequelae that are dependent on the time

in which reperfusion is achieved<sup>19</sup>. Therefore, it is necessary to create animal models that allow the evaluation of different interventions for this pathology and that are accessible to different research institutions. Three surgical procedures with affordable materials that reversibly occlude the middle cerebral artery are presented here. Considering the total cost of disposable materials, we believe that this can be reproduced in neuroscience laboratories that cannot access more complex materials.

Although the three surgical techniques were reproducible in cadaveric models, it should be noted that standardization of both techniques is necessary in pilot studies with anesthetized animals before proceeding to evaluate ischemic lesions. Similarly, the favorable findings could vary in in-vivo models, such as the use of tissue spacers made with common clips. In the cadaveric model described, it was possible to observe that the tissue spacers traction the neck muscles well without leaving any apparent lesion, giving a large visual field. Similarly, as the specimens used were less than 5 minutes after being sacrificed, the mobility and elasticity of the neck muscles is expected to be equal to an in-vivo model. Nevertheless, is not possible to know based on these results to know if the prolonged use of intraoperative tissue spacers could considerably alter the anatomy of the neck and complicate the postoperative period. Even so, it is possible to speculate that one of the potential damages to evaluate are the limitations for swallowing and breathing given that these muscles fulfill these functions.

Similarly, the vascular clamp made with soft wire also prevented bleeding at the time of inserting the catheter. However, we were unable to assess in this cadaveric model whether the vessel occluded with the vascular clamp would still be permeable to blood flow. It is also necessary to evaluate in in vivo models whether these vascular clamps can generate thrombosis and reperfusion. Finally, the cauterizer was able to cauterize the pterygopalatine and thyroid arteries without releasing pooled blood from the vessels in the process. But it is necessary to be careful when using the cautery to avoid burn injuries to adjacent tissues. The hook-shaped cautery can prevent this by traction on the tissue to be cauterized, avoiding contact with other tissues. Even so, continuous blood flow in an in-vivo model might not obtain this result and could easily coagulate.

Despite all this, the current model has advantages for the surgeon, such as the ease of having a large visual field of the vascular bundle. In other models of intraluminal occlusion, microscopes or high-magnification lenses are required to be able to visualize the vascular bundle making it difficult to manipulate the tissue. But in present surgical technique these elements were not required. Additionally, dissection and traction of the neck muscles did not expose important structures such as the trachea or other nerves in the neck. Finally, the use of the ESD-15 forceps made it possible to easily dissect all the tissues and the G-31 or G-22 hypodermic needle facilitates the manipulation of the vascular bundle and the introduction of the catheter into the vessels. Usually in models that involve the catheterization of an artery, microscissors are used, both for performing the partial arteriotomy and the dissection of the adjacent vascular tissue<sup>20,21</sup>. But the use of microscissors can be risky and requires absolute mastery of the tool to prevent unwanted vascular injuries or even a total arteriotomy<sup>22</sup>.

Developed catheters were also easy to produce, standardized, reproducible and could be made in other sizes, by knowing the internal diameter of the hypodermic needles<sup>23</sup>. In fact, the idea of using the temperature generated by lamps or bulbs to obtain the desired size of the catheters had already been proposed. however, this is not easily reproducible due to changes in the diameter sizes. So, the method presented here to obtain the desired size from the internal diameter of hypodermic needles meets reproducibility objectives<sup>24</sup>. Despite this, to ensure the sterility of silicone-tipped catheters, thermal methods should not be used since the silicone used is hot-melt<sup>25</sup>, on the other hand, ultraviolet light or ethylene oxide should be considered as alternatives<sup>26</sup>. Additionally, it is necessary for the silicone tips to be coated with poly-L-lysine to ensure local infarction and avoid subarachnoid hemorrhage or vessel injury<sup>27,28</sup>.

All the presented results must be taken with caution as all of them were presented in cadaveric models as does not present the challenges of a living animal. Because the lack of those challenges, cadaveric models are suitable for surgical training or surgical standardization. Being able to train without the challenges of a live animal allows to fulfill one of the 3 R's<sup>29</sup> that is sought in any study with animals, which is refinement. At the same time, because the researcher manages to master the technique, it also allows him to fulfill the R of reducing the use of animals, by reducing the variability

that can be generated by surgical procedures. Therefore, the results presented in this study allow to refine and reduce the use of laboratory animals.

## CONCLUSIONS

The current model allows training for the occlusion of the internal carotid artery and the middle cerebral artery in a cadaveric model in an affordable way, but it is necessary to replicate this model *in vivo* to confirm the feasibility and reproducibility as in other models.

## ACKNOWLEDGEMENTS

We thank the neuroscience and behavior laboratory of the Universidad de los Andes and the comparative biology unit of the Pontificia Universidad Javeriana for donating the animals and providing the space, and Andrea Navas-Olive for providing us with the illustrated Figures.

## Financial Support

The authors declare that no financial support was received.

## REFERENCES

- Grysiewicz RA, Thomas K, Pandey DK. Epidemiology of ischemic and hemorrhagic stroke: incidence, prevalence, mortality, and risk factors. *Neurol Clin.* 2008;26(4):871-95, vii. <http://dx.doi.org/10.1016/j.ncl.2008.07.003>. PMID:19026895.
- Meng L, Hou W, Chui J, Han R, Gelb AW. Cardiac output and cerebral blood flow: the integrated regulation of brain perfusion in adult humans. *Anesthesiology.* 2015;123(5):1198-208. <http://dx.doi.org/10.1097/ALN.0000000000000872>. PMID:26402848.
- Willie CK, Tzeng YC, Fisher JA, Ainslie PN. Integrative regulation of human brain blood flow. *J Physiol.* 2014;592(5):841-59. <http://dx.doi.org/10.1113/jphysiol.2013.268953>. PMID:24396059.
- Ginsberg MD. Neuroprotection for ischemic stroke: past, present and future. *Neuropharmacology.* 2008;55(3):363-89. <http://dx.doi.org/10.1016/j.neuropharm.2007.12.007>. PMID:18308347.
- Macrez R, Ali C, Toutirais O, et al. Stroke and the immune system: from pathophysiology to new therapeutic strategies. *Lancet Neurol.* 2011;10(5):471-80. [http://dx.doi.org/10.1016/S1474-4422\(11\)70066-7](http://dx.doi.org/10.1016/S1474-4422(11)70066-7). PMID:21511199.
- Murray V, Norrving B, Sandercock PAG, Terént A, Wardlaw JM, Wester P. The molecular basis of thrombolysis and its clinical application in stroke. *J Intern Med.* 2010;267(2):191-208. <http://dx.doi.org/10.1111/j.1365-2796.2009.02205.x>. PMID:20175866.
- Patel RA, McMullen PW. Neuroprotection in the treatment of acute ischemic stroke. *Prog Cardiovasc Dis.* 2017;59(6):542-8. <http://dx.doi.org/10.1016/j.pcad.2017.04.005>. PMID:28465001.
- Hemmen TM, Lyden PD. Multimodal neuroprotective therapy with induced hypothermia after ischemic stroke. *Stroke.* 2009;40(3, Suppl):126-8. <http://dx.doi.org/10.1161/STROKEAHA.108.533083>. PMID:19064802.
- Linares G, Mayer SA. Hypothermia for the treatment of ischemic and hemorrhagic stroke. *Crit Care Med.* 2009;37(7, Suppl):S243-9. <http://dx.doi.org/10.1097/CCM.0b013e3181aa5de1>. PMID:19535954.
- Schwab S, Spranger M, Schwarz S, Hacke W. Barbiturate coma in severe hemispheric stroke: useful or obsolete? *Neurology.* 1997;48(6):1608-13. <http://dx.doi.org/10.1212/WNL.48.6.1608>. PMID:9191775.
- Woodruff TM, Thundyil J, Tang SC, Sobey CG, Taylor SM, Arumugam TV. Pathophysiology, treatment, and animal and cellular models of human ischemic stroke. *Mol Neurodegener.* 2011;6(1):11. <http://dx.doi.org/10.1186/1750-1326-6-11>. PMID:21266064.
- Hossmann KA. The two pathophysiologicals of focal brain ischemia: implications for translational stroke research. *J Cereb Blood Flow Metab.* 2012;32(7):1310-6. <http://dx.doi.org/10.1038/jcbfm.2011.186>. PMID:22234335.
- Liu S, Zhen G, Meloni BP, Campbell K, Winn HR. RODENT STROKE MODEL GUIDELINES FOR PRECLINICAL STROKE TRIALS (1ST EDITION). *J Exp Stroke Transl Med.* 2009;2(2):2-27. <http://dx.doi.org/10.6030/1939-067X-2.2.2>. PMID:20369026.
- Belayev L, Endres M, Prinz V. Focal cerebral ischemia in the mouse and rat by intraluminal suture. *Neuromethods.* 2016;120:31-43. [http://dx.doi.org/10.1007/978-1-4939-5620-3\\_4](http://dx.doi.org/10.1007/978-1-4939-5620-3_4).

15. Mhairi Macrae I. Focal ischemia models: middle cerebral artery occlusion induced by electrocoagulation, occluding devices, and endothelin-1. *Neuromethods*. 2016;120:45-58. [http://dx.doi.org/10.1007/978-1-4939-5620-3\\_5](http://dx.doi.org/10.1007/978-1-4939-5620-3_5).
16. Uluç K, Miranpuri A, Kujoth GC, Aktüre E, Başkaya MK. Focal cerebral ischemia model by endovascular suture occlusion of the middle cerebral artery in the rat. *J Vis Exp*. 2011;48(48):e1978. PMID:21339721.
17. Leary S, Underwood W, Lilly E, et al. *AVMA Guidelines for the Euthanasia of Animals*. year editi. Schaumburg: American Veterinary Medical Association; 2013.
18. WHO. Global status report on noncommunicable diseases 2014: attaining the nine global noncommunicable diseases targets; a shared responsibility [Internet]. 2014 [cited 2018 Dec 9]. [http://apps.who.int/iris/bitstream/handle/10665/148114/9789241564854\\_eng.pdf;jsessionid=685CFD077ABE1DCCB6BD7637B56CC243?sequence=1](http://apps.who.int/iris/bitstream/handle/10665/148114/9789241564854_eng.pdf;jsessionid=685CFD077ABE1DCCB6BD7637B56CC243?sequence=1)
19. Walker MF, Hoffmann TC, Brady MC, et al. Improving the development, monitoring and reporting of stroke rehabilitation research: consensus-based core recommendations from the stroke recovery and rehabilitation roundtable. *Neurorehabil Neural Repair*. 2017;31(10-11):877-84. <http://dx.doi.org/10.1177/1545968317732686>. PMID:29233072.
20. Couceiro J, Castro R, Tien H, Ozyurekoglu T. Step by step: microsurgical training method combining two nonliving animal models. *J Vis Exp*. 2015;2015(99):e52625. PMID:25992633.
21. Jespersen B, Knupp L, Northcott CA. Femoral arterial and venous catheterization for blood sampling, drug administration and conscious blood pressure and heart rate measurements. *J Vis Exp*. 2012;(59):1-8. PMID:22297665.
22. Heiser A. Rat jugular vein and carotid artery catheterization for acute survival [Internet]. New York: Springer Science; 2007 [cited 2023 Dec 26]. [https://books.google.com.co/books?hl=en&lr=&id=0JXZBgo-nSMC&oi=fnd&pg=PP6&dq=Rat+Jugular+Vein+and+Carotid+Artery+Catheterization+for+Acute+Survival+Studies&ots=9LnU-3clza0&sig=UxzrFE5yPFiBr\\_yrGAXPhwabY5A#v=onepage&q=Rat%20Jugular%20Vein%20and%20Carotid%20Artery%20Catheterization%20for%20Acute%20Survival%20Studies&f=false](https://books.google.com.co/books?hl=en&lr=&id=0JXZBgo-nSMC&oi=fnd&pg=PP6&dq=Rat+Jugular+Vein+and+Carotid+Artery+Catheterization+for+Acute+Survival+Studies&ots=9LnU-3clza0&sig=UxzrFE5yPFiBr_yrGAXPhwabY5A#v=onepage&q=Rat%20Jugular%20Vein%20and%20Carotid%20Artery%20Catheterization%20for%20Acute%20Survival%20Studies&f=false)
23. Wang-Fischer Y, Divani AA, Prado R, Koetzner L. Surgical models of stroke induced by intraluminal filament implantation. In: Wang-Fischer Y, editor. *Manual of stroke models in rats*. Boca Raton: CRC Press; 2008. p. 107-26. <http://dx.doi.org/10.1201/9781420009521-13>.
24. Su MF, Pan YC. Introduction to Microsurgery and Training. In: Dibart S, editor. *Practical periodontal plastic surgery*. Iowa: John Wiley & Sons; 2017. p. 8–12. <http://dx.doi.org/10.1002/9781119014775.ch3>.
25. Zheng M, Luo X, Chen J, Shi S, Liu J, Chen X. Hot-melt adhesives for medical applications. *Chinese Journal of Tissue Engineering Research*. 2016;20(38):5758.
26. Wu Y, Hu L, Yang X, et al. Intraluminal spindle-shaped-head suture induced occlusion of middle cerebral artery in the rats. *Neurol Res*. 2017;39(11):1028-36. <http://dx.doi.org/10.1080/01616412.2017.1375661>. PMID:28936922.
27. Engel O, Kolodziej S, Dirnagl U, Prinz V. Modeling Stroke in Mice - Middle Cerebral Artery Occlusion with the Filament Model. *J Vis Exp*. 2011;47(47):2423. PMID:21248698.
28. Zhao H, Mayhan WG, Sun H. A modified suture technique produces consistent cerebral infarction in rats. *Brain Res*. 2008;1246:158-66. <http://dx.doi.org/10.1016/j.brainres.2008.08.096>. PMID:18840416.
29. Graham ML, Prescott MJ. The multifactorial role of the 3Rs in shifting the harm-benefit analysis in animal models of disease. *Eur J Pharmacol*. 2015;759:19-29. <http://dx.doi.org/10.1016/j.ejphar.2015.03.040>. PMID:25823812.

## Supplementary Material

Supplementary material accompanies this paper.

Supplay material to facilitate the surgical reproducibility

This material is available as part of the online article from <https://drive.google.com/file/d/1dzkdrPlcYqawDV5pk3uG9AKmqhY9thpx/view?usp=sharing>